Fermi National Accelerator Laboratory

FN-409
1183.000

FAST NEUTRONS AND MISONIDAZOLE FOR MALIGNANT ASTROCYTOMAS

P. D. Kurup, T. F. Pajak, F. R. Hendrickson, J. S. Nelson, J. Mansell,
L. Cohen, M. Awschalom, I. Rosenberg, and R. K. Ten Haken

September 1984

Operated by Universities Research Association Inc. under contract with the United States Department of Energy

Fast Neutrons and Misonidazole For Malignant Astrocytomas

Parvathy D. Kurup, M.D., Thomas F. Pajak, Ph.D.,[†]
Frank R. Hendrickson, M.D., James S. Nelson, M.D.,[‡]
JoAnne Mansell, R.N., P.A., Lionel Cohen, M.D., Miguel Awschalom, Ph.D.,
Ivan Rosenberg, Ph.D.,[*] Randall K. Ten Haken, Ph.D.

Fermilab Neutron Therapy Facility, P.O. Box 500, Batavia, IL 60510

† Radiation Therapy Oncology Group, 925 Chestnut St., Philadelphia, PA 19107

‡ Department of Pathology, Washington University School of Medicine, 660 S. Euclid Avenue., St. Louis, Missouri 63110

*Radiation Therapy Dept., St. Joseph Hospital, Elgin, IL 60120

ABSTRACT

Twenty-five patients with biopsy proven malignant supratentorial astrocytomas were entered into a Phase I/II study of misonidazole combined with neutron radiation at Fermilab Neutron Therapy Facility (NTF) between August 1979 and April 1981. The main objectives were to determine tissue tolerance in terms of acute and late effects, and to estimate tumor clearance and survival rates. The total dose was 18.0 Gy given in weekly fractions of 3.0 Gy over 39 days. Four hours before each irradiation, 2.5 gm/m^2 misonidazole was administered orally. Patients' ages ranged from 28-69 years. Karnofsky status for most patients was 80 or 90; the lowest grade was 60. The majority of patients had glioblastoma multiforme. Most were already on steroids prior to initiation of therapy.

The median survival for the whole group was 12.0 months; 25% were alive at 18 months with some neurological compromise. The median survival remained unchanged for subgroups of patients with ages between 40-60 years and with Karnofsky performance status above 80. Among the 19 patients with glioblastoma multiforme, the median survival was 10 months. Acute toxicity was within tolerable limits. Details of toxicity and tissue analysis from post mortems and second craniotomy samples are presented.

INTRODUCTION

Primary brain tumors have continued to be a difficult problem for oncologists. Recent United States statistics[4] indicate that approximately 12,800 new cases of primary brain and central nervous system tumors occur each year, and approximately 2.5% of all cancer related deaths are from primary brain tumors. Malignant astrocytomas tend to be infiltrating in character and can rarely be completely excised. Even after apparent total resection, recurrence occurs frequently.[22] Radiation therapy is therefore an important part of overall management. Post-operative conventional radiation therapy with photons prolongs median survival and enhances the quality of survival.[25,27,33] However, reported survival frequencies range from 55-67% at 6 months to 8-20% at 24 months. Patients are killed by relentless local growth of tumor rather than metastases.

Investigators in recent years have shown considerable interest in exploring new therapeutic options. Higher doses in conventional photon irradiation,[26,27,33] and combining photon irradiation with chemotherapeutic agents[9,19,28,32] that cross the blood brain barrier have been studied. High linear energy transfer (LET) radiations such as neutrons or pi-mesons have been used alone and in combination with conventional radiation.

Hypoxic cells are known to be present surrounding the necrotic areas in all solid tumors, and most malignant gliomas have multiple areas of necrosis.[20] Possibly, the necrosis may be a further indication of the hypoxic state. The hypoxic cell population is thought to be less responsive to the effects of conventional photon radiation since the presence of oxygen is important in determining tissue response to ionizing radiations.[14] Attempts to improve the killing of hypoxic cells have involved the use of hyperbaric oxygen,[8] hypoxic cell sensitizers[5,11,17,19,30,31,] and high-LET radiation.[6,7,16,18,21] Neutron irradiation potentially has the radiobiological advantage of a lower OER (oxygen enhancement ratio) which is expected to be beneficial when large hypoxic cell populations are present.[12,14,15] Of the sensitizers, the misonidazoles have been used the most in clinical studies. Animal experiments have suggested a reduction of OER from about 1.6 for neutrons alone to nearly 1.0 in combination with hypoxic cell sensitizers.[14] A Phase II study was conducted at the Fermilab NTF to evaluate the feasibility and toxicity of combining neutron irradiations with misonidazole at weekly intervals. The results are described in detail in this report.

METHODS AND MATERIALS

From August 1979 to April 1981, 25 patients with malignant astrocytomas were entered into a Phase II study (RTOG 79-03) at Fermilab NTF. Informed consent was obtained from all patients after explaining the nature of the treatment program. Fast neutrons are produced by bombarding a 22 mm thick beryllium target with 66 MeV protons from a linear accelerator.[1,10] The skin sparing and depth dose characteristics are similar to those of 6 MeV X-rays from a linear accelerator.[2,3,24,29] The relative biological effectiveness (RBE) of the beam is approximately 3 for most tissues,[15,23] but is considered to be higher for the central nervous system. Patients were treated in a sitting position in an adjustable chair. Immobilization of the head was achieved with individually made plastic masks.[(a)] The neutron beam is fixed horizontally. However, all the relative movements provided by conventional isocentric therapy can be achieved with the chair, since it moves in three dimensions and rotates about a vertical axis. The source axis distance is 190 cm. Four intersecting laser beams help in the proper alignment of the patient. Planning X-rays are done and individual treatment plans are generated in the same chair. The neutron doses reported are actually total absorbed doses which include the gamma ray component.

TREATMENT TECHNIQUE

Patients were treated once a week for 6 weeks with 3.0 neutron Gy per fraction. The whole brain received 12.0 Gy in 4 weeks and boosts to the tumor bed brought the total dose to 18.0 Gy. The whole brain treatments were done with parallel opposing lateral fields with dose calculated at the midplane. The boost was given with single or multiple fields using wedges as needed. Target volume for the boost was determined with the help of CT scans. Figure 1 is a representative isodose distribution. Misonidazole, 2.5 gm/m^2, was given orally 4 hours prior to each neutron irradiation. Blood levels of misonidazole were determined each week.

FOLLOW-UP

Patients were seen in first follow-up 2-3 weeks after completion of planned treatment and every 2-3 months thereafer. A physical examination, including a detailed neurological examination, was done to assess the toxicity as well as the effectiveness of therapy. CT scans were done at referring institutions and received at our follow-up clinic to help in these evaluations. In addition, many of the second craniotomy or autopsy specimens were studied in detail by the same pathologist who reviewed the original biopsy material.

The objectives of our study were (1) to lay the basis for a Phase III study with photons versus neutrons in combination with misonidazole; (2) to determine the tolerance of the brain to the unusual radiation doses and fractionation in terms of acute and late normal tissue reaction; and (3) to establish the tumor clearance rate, disease free interval, and the prospect for long-term tumor control.

RESULTS

Of the 25 patients treated with fast neutrons in combination with misonidazole, one patient is not eligible for evaluation because she was a 14 year-old girl with a brain stem lesion. Two other patients who did not complete the whole course of irradiations are included in the analysis.

Age, Sex and Performance Status. Ages ranged from 28-69 years (median: 52 years). Eight patients were under 40 years at the time of diagnosis and 5 were 60 years or more. The male to female ratio was 2:1. Karnofsky performance scale was used to evaluate the general condition of the patient. Karnofsky status for 21 out of 24 patients was 80 or 90.

Location and Size of Tumor and Extent of Surgery. Many of the lesions involved the frontal lobe. Parietal, temporal and occipital lobes were involved with equal frequency in this series. The sizes of the tumors were estimated from pre-operative CT scans; 21 of the 24 patients had lesions measuring 5-10 cm. In one patient the lesion measured less than 5 cm and two had tumors larger than 10 cm. Except for one patient who underwent biopsy only, all others had subtotal resection of their tumor at the time of craniotomy and initial diagnosis.

Pathology. Diagnoses of glioblastoma multiforme or Grade IV astrocytoma were made on 16 patients at their referring institutions. The tumor from one patient was diagnosed as a Grade III-IV lesion. Seven patients had a diagnosis of anaplastic malignant astrocytoma or Grade III astrocytoma. The pre-treatment slides of 24 of the 25 patients were submitted by the referring institutions and reviewed by one of the authors (J.S.N.). The review diagnosis in 19 patients (including the ineligible patient) was glioblastoma multiforme. The tumors from the 5 other patients were each diagnosed as astrocytoma with atypical or anaplastic foci.[20] The patient whose pre-treatment slides were not available for pathology review died after receiving only one radiation treatment. The pathology review examination of histologic sections taken at autopsy from the tumor site disclosed a mixed glioma (oligodendroglioma and astrocytoma). Some atypical appearing tumor cells were present. Radiation necrosis was not

evident.

Neurological Status. In 16 patients, the major symptoms at presentation were due to increased intracranial pressure, e.g., headache, nausea, and seizures. Six patients had weakness of muscles or partial paralysis, and four had sensory symptoms. Visual problems were reported by seven patients while six patients were noted to have had personality changes. Major neurological deficits were present in only two patients. Six patients had moderate impairment of motor and/or sensory functions. No neurological deficit was seen in 16 patients prior to neutron irradiation.

Treatment. All patients received steroids concomitantly. Neutrons were delivered in full doses to 22 patients. One patient received only 3.0 Gy and another received only 9.0 Gy. Nineteen of the 24 patients received a full course of misonidazole, as required in the protocol. The two patients who did not complete the irradiation also did not receive the full misonidazole dose. In the remaining three patients, five out of the six doses of misonidazole were given. The omission of the last dose was because of acute reactions in one of these patients. Two patients each missed one neutron irradiation because of accelerator problems after taking the misonidazole as scheduled. When the neutron dose was given, the misonidazole could not be repeated because of limitations on total dose.

Survival. Actuarial analysis of survival for the whole group is shown graphically in Figure 2. Overall median survival is 12.0 months. The influence of important prognostic factors such as age, Karnofsky performance status, and histology was studied. Median survival for the eight patients under 40 years is 20.0 months and for the group 40-59 years, it is 12.0 months. In the older group of patients (five of them over 60 years) median survival is only six months. Twenty-one of the 24 patients had a Karnofsky performance score of 80 or over, with a median survival of 12.0 months. In the five patients with diagnoses of atypical or anaplastic astrocytoma, the duration of survival after therapy ranges from 15.0 to 36.0 months, with a median survival of 20.0 months. Median survival in the group with glioblastoma multiforme (18 patients) is 10.0 months. Among the 24 evaluable patients, 25% were alive at 18 months and 12.5% at two years. Only 2 patients lived 3 years post-treatment.

Quality of Survival. Five patients did not show any improvement following treatments. The rest had improvement in their general and neurological status for periods ranging from 3-16 months. In 6 patients, deterioration started within 6 months of treatment while 10 patients had good neurological function for up to 12 months. Only three patients had good quality neurological function for more than 12 months.

Acute Reactions. Nine patients reported no acute reactions with this treatment schedule. Ten patients experienced nausea, vomiting and headaches of short duration. These symptoms were well controlled with medication. Such symptoms are often produced by intracranial pressure. Transient skin rashes were noticed by two patients. These patients were also taking steroids, phenytoin and phenobarbitol. Four patients developed the sensory symptoms of numbness and hyperesthesia of the extremities. Recovery was spontaneous in all patients within one to four months. Only one patient developed a fever of 40°C with chills, and another patient had transient episodes of left ear deafness which resolved spontaneously in two to three months.

TUMOR CLEARANCE AND LATE EFFECTS

Radiographic

CT scans were used to estimate tumor clearance radiographically. Thee first follow-up scan was done two to three months after the initiation of therapy. Of the 22 patients where scans were available, 10 showed definite improvement in the radiographic appearance. Figure 3a is the CT scan of a patient taken one month prior to initiation of neutron therapy. A large left frontoparietal tumor is demonstrated. An excisional biopsy was performed prior to neutron irradiation. Figure 3b is a CT scan of the same patient taken 7 months later. The lesion is no

longer obvious. Appearance was stable in three patients and there was a suggestion of progression of tumor in 6 patients. In another three patients, although tumor itself was not progressing, there was a low density area suggesting edema, which was thought to be a radiation reaction.

Histopathological

Brain tissue including the tumor site was available for histopathological examination from 13 patients following treatment. The histologic specimens were obtained from second craniotomies and debulking surgery and/or autopsies (Table 1). The following account is a brief summary of the prinicpal pathologic findings in these tissues. A detailed study of this material by one of the authors (J.S.N.) is in progress and will be reported in a separate paper. Residual tumor was identified in 12 of the 13 tissues studied. In 6, the histologic diagnoses on the pre- and post-treatment specimens coincided. In each of the other 6 patients the pre-treatment histologic diagnosis had been glioblastoma multiforme. The post-treatment tumor in these patients, however, lacked the cell density, pleomorphism, and other characteristic features of glioblastoma multiforme. The cell density in these tumors was moderate, and the degree of cellular pleomorphism was variable. Vascular hyperplasia and pseudopalisades with central necrosis were absent. Evidence of

radiation necrosis with typical vascular changes, chiefly affecting the white matter, was evident in each of the 13 cases. The patient with the mixed oligodenroglioma-astrocytoma is not included in the above statistics. This patient had only one dose of misonidazole and one fraction of neutron radiation. The pre-treatment specimen from this patient was not available for pathology review.

COMPARISON WITH OTHER RTOG GLIOMA STUDIES

Another group of 31 consecutive patients was subsequently treated with the same neutron schedule, but without misonidazole. Their median survival was 12.0 months (unpublished data). Since 88% of the evaluable patients in the neutron with misonidazole study had initially favorable Karnofsky performance scores of 80 or higher, the comparison between the two neutron treated patient groups was restricted to patients with such favorable scores. The patient characteristics for both groups are shown in Table 2. Figure 4 shows the historical survival comparison between the patients treated with neutrons and misonidazole versus neutrons only. The two survival curves are very similar, suggesting no augmentation by the misonidazole. Subsequently, patients treated with neutrons with or without the misonidazole were grouped together for comparison with two treatment schedules from other glioma studies.[9,13] One schedule employed conventional photon radiation to a total dose of 60.0 Gy and was a part of a previous

Radiation Therapy Oncology Group (RTOG) study.[9]

The other schedule employed a conventional photon radiation with a total dose of 70.0 Gy which included a boost of 10.0 Gy. This schedule was the control arm of the RTOG randomized study comparing a photon boost against a neutron boost.[13]

The subsequent survival comparison was restricted to glioblastoma multiforme patients with initially favorable Karnofsky performance scores of 80 or over, in order to reduce the amount of non-homogeneity among the treatment groups with respect to significant prognostic factors. The distribution of patients according to various prognostic criteria is shown in Table 3. No survival advantage is shown for patients treated with neutrons only or in combination with misonidazole when compared with conventional radiation (60.0 Gy) (Fig. 5). The group that was treated with photons (60.0 Gy) with a boost (10.0 Gy) showed slight but statistically insignificant differences in the latter part of the survival curves (p=.21).

DISCUSSION

This report deals with a unique study in which an attempt was made to attack the 'hypoxic' cell population in a situation where relentless regrowth of tumor in the local area has been the major

problem. Fast neutron irradiation was used in the past, and pilot studies demonstrated the potential for tumor control.[7,18,21] However, many of the patients so treated died of radiation necrosis and other related complications. Combining neutrons with conventional photon irradiation,[13] or reducing the dose of neutrons,[16] resulted in failure with persistent tumor. Misonidazole combined with conventional radiation yielded survival rates similar to conventional radiation therapy alone.[5,11,17,30,31] No augmentation for misonidazole (plus radiation and BCNU) was shown in a randomized study where the control patients received radiation and BCNU[19] without misonidazole.

The present study has combined high-LET radiation with the hypoxic cell sensitizer misonidazole. The major difference in prognostic factors compared to other studies is in the Karnofsky performance status. Twenty-one out of 24 patients from the present series had a Karnofsky performance status over 80. Also, the majority of patients did not have any major neurological deficit since tumors were located in non-critical areas. All underwent subtotal resection, except for one patient who had only a biopsy prior to neutron irradiation. This particular patient died after one fraction of neutron treatment.

One of the authors (J.S.N.) has demonstrated that the presence of coagulation necrosis involving astrocytic tumor cells is a major prognostic criterion with regard to malignant supratentorial astrocytomas.[20] The usefulness of this criterion with regard to prognosis, however, is limited in the case of malignant astrocytomas following radiation treatment. This type of therapy frequently induces necrosis within the tumor that is indistinguishable from the spontaneously occurring necrosis characteristic of glioblastoma multiforme. In the present study the diagnosis of glioblastoma multiforme was made on post-treatment specimens only when the following histologic features were present: marked cell density and pleomorphism; pseudopalisades with central necrosis; and vascular hyperplasia with formation of glomeruloid structures. As noted previously, in 6 patients the histologic characteristics of the post-treatment tumor had changed from those characteristic of glioblastoma to those suggestive of a somewhat less aggressive type of malignant astrocytoma. Little is known, however, about the correlation between the histologic appearance of malignant astrocytomas following neutron treatment and their subsequent biological behavior. It is not clear whether the residual less aggressive tumor would eventually develop into frank glioblastoma multiforme or continue to grow in a less aggressive manner. This area requires further investigation.

No augmentation for misonidazole could be shown when the survival curves of the two groups of patients treated with similar doses of neutron radiation, with or without misonidazole, were compared (Fig. 4). No survival advantage was shown for neutron treated patients compared to conventional radiation (Fig. 5). The survival curve of patients treated with 18.0 Gy (Fermi) was almost identical to the photon group receiving 60.0 Gy. Also, persistent or recurrent tumor was identified in post-irradiation specimens whenever tissue was available for histopathological examinations.

Animal experiments and pilot studies with fast neutrons[7,18] had suggested the possibility of a higher RBE for the central nervous system. Results from the current study seem to suggest that the RBE may be higher for normal tissues in the central nervous system but not necessarily for central nervous system tumors. The absence of survival advantage over conventional radiation suggests that re-oxygenation may take place much more effectively than we believed. Hence, the presumed advantage of low OER becomes merely theoretical. Attempts to improve hypoxic cell killing by hyperbaric oxygen[8] and hypoxic cell sensitizers with conventional radiation[5,11,17,19,30,31] were also shown to be ineffective in clinical situations.

CONCLUSIONS

(1) Acute tolerance of brain tissue to the unusual combination of dose and fractionation is acceptable.

(2) Comparison of survival rates for the current study do not show any advantage over conventional irradiation.

(3) Histopathological analysis reveals the absence of a therapeutic window since residual tumor and radiation necrosis are both documented with the treatment schedule used.

Since residual tumor and radiation necrosis are both documented with the treatment schedule used, the histopathological analysis appears to indicate the absence of a therapeutic window, that is, a treatment level at which tumor ablation can be achieved without radionecrosis.

ACKNOWLEDGMENTS

This investigation was supported by PHS Grant Number P01CA18081-09, awarded by the National Cancer Institute, DHHS. Appropriate informed consent statements were obtained from all Fermilab patients participating in this study. The authors would like to thank Ms. Michelle Gleason for helping to prepare this manuscript.

REFERENCES

(a) Light Cast, Merck, Sharp & Dohme, Orthopedics Co., Inc., Costa Mesa, CA.

1. Awschalom, M., Grumboski, L., Hrejsa, A. F., Lee, G. M., and Rosenberg, I.: The Fermilab Cancer Therapy Facility: Status Report after 2.5 Years of Operation. Trans. Nucl. Sci. NS-26: 3068-3070, 1979.

2. Awschalom, M., and Rosenberg, I.: Characterization of a p(66)Be(49) Neutron Therapy Beam. II. Skin-Sparing and Dose Transition Effects. Med. Phys. 8: 105-107, 1981.

3. Awschalom, M., Rosenberg, I., Ten Haken, R., Cohen, L., Hendrickson, F.: The Fermilab Neutron Therapy Facility treatment planning for neutron and mixed beams, Strahlentherapie 77: 144-149, 1981.

4. Cancer Statistics, 1984. Ca - A Cancer Journal for Clinicians (Published by the American Cancer Society). Vol 34, pp. 7-23, Jan/Feb 1984.

5. Carabell, S. C., Bruno, L. A., Weinstein, A. S., Richter, M. P., Chang C. H., Weiler, C. B., Goodman, R. L.: Misonidazole and Radiotherapy to Treat Malignant Glioma: A Phase II Trial of the RTOG. Int. J. Radiat. Oncol. Biol. Phys. 7: 71-77, 1981.

6. Catterall, M., and Bewley, D. K.: Fast Neutrons in the Treatment of Cancer. Academic Press, London, 1979.

7. Catterall, M., Bloom, H. J. G., Ash, D. V., Walsh, L., Richardson, A., Uttley, D., Gowing, N. F. C., Lewis, P., Chancer, B.: Fast Neutrons Compared with Megavoltage X-rays in the Treatment of Patients with Supratentorial Glioblastoma: A Controlled Study. Int. J. Radiat. Oncol. Biol. Phys. Vol 6, 261-266, 1980.

8. Chang, C. H.: Hyperbaric Oxygen and Radiation Therapy in the Management of Glioblastoma. National Cancer Inst. Monogr. 46: 163-169, 1977.

9. Chang, C. H., Horton, J., Schoenfeld, D., Salazar, O., Perez-Tamayo, R., Kramer, S., Weinstein, A., Nelson, J. S., Tsukada, Y.: Comparison of Post-operative Radiotherapy and Combined Post-operative Radiotherapy and Chemotherapy in the Multidisciplinary Management of Malignant Gliomas. A Joint RTOG-ECOG Study. Cancer 52: 997-1007, 1983.

10. Cohen, L., and Awschalom, M.: The Cancer Therapy Facility at the Fermi National Accelerator Laboratory: A Preliminary Report. Appl. Radiol. 5: 55, 1976.

11. EORTC Brain Tumor Group: Misonidazole in radiotherapy of supratentorial malignant brain gliomas in adult patients: A randomized double-blind study. Eur. J. Cancer Clin. Oncol. 19: 39-42, 1983.

12. Gragg, R. L., Humphrey, R. M., Meyer, R. E.: The Response of Chinese Hamster Ovary Cells in Fast Neutron Radiotherapy Beams. II. Sublethal and Potentially Lethal Damage Recovery Capabilities. Radiat. Res. 71: 461-470, 1977.

13. Griffin, T. W., Davis, R. B., Laramore, G. E., Nelson, J. S., Hendrickson, F. R., Rodriguez-Antunez, A., and Hussey, D. H.: Fast

Neutron Irradiation for Glioblastoma Multiforme: Results of an RTOG Phase III Study. Am. J. Clin. Oncol., 6: 661-667, 1983.

14. Hall, E. J.: Radiobiology for the Radiologist. Harper and Rowe, Hagerstown, MD, 1978.

15. Hall, E. J., Kraljeire, U.: Repair of Potentially Lethal Radiation Damage: Comparison of Neutron and X-ray RBE and Implications of Radiation Therapy. Radiology 120: 731-735, 1976.

16. Herskovic, A., Ornitz, R. D., Shell, M., Rogers, C. C.: Treatment experience glioblastoma multiforme treated with 15 MeV fast neutrons. Cancer 49: 2463-2465, 1982.

17. Kapp, D. S., Wagner, F. C., Lawrence, R.: Glioblastoma multiforme: Treatment by large dose fraction irradiation and

Metronidazole. Int. J. Radiat. Oncol. Biol. Phys. 8: 351-355, 1982.

18. Laramore, G. E., Griffin, T. W., Gerdes, A. J., Pancer, R. G.,: Fast Neutron and Mixed Beam Teletherapy for Grades III and IV Astrocytomas. Cancer 42: 96-103, 1978.

19. Nelson, D. F., Schoenfeld, D., Weinstein, A. S., Nelson, J. S., Wasserman, T., Goodman, R. L., and Carabell, S.: A Randomized Comparison of Misonidazole Sensitized Radiotherapy Plus BCNU and Radiotherapy plus BCNU for Treatment of Malignant Glioma After surgery: Preliminary Results of an RTOG Study. Int. J. Rad. Oncol. Biol. Phys. 9: 1143-1151, 1983.

20. Nelson, J. S., Tsukada, Y., Schoenfeld, D., Fulling, K., Lamarche, J., Peress, N.: Necrosis as a Prognostic Criterion in Malignant Supratentorial, Astrocytic Gliomas. Cancer 52: 550-554,

1983.

21. Parker, R. G., Berry, H. C., Gerdes, A. J., Soronen, M. D., Shaw, C. M.: Fast Neutrons Beam Radiotherapy of Glioblastoma Multiforme. American J. Roent. Genol. 127: 331-335, 1976.

22. Ransohoff, J.: Surgical Management of Malignant Brain Tumors. National Cancer Institute Monograph No: 46 pp., 145-150, 1977.

23. Redpath, J. L., David, R. M., Cohen, L.: Dose Fractionation Studies on Mouse Gut and Marrow: An Intercomparison of 6 MeV Photons and Fast Neutrons ($\bar{E}$ = 25 MeV). Radiation Research 75: 642-648, 1978.

24. Rosenberg, I., and Awschalom, M.: Characterization of a p(66)Be(49) Neutron Therapy Beam: I. Central Axis Depth Dose and

Off-axis Ratios. Med. Phys. 8: 99-104, 1981.

25. Rutten, E-H. J. M., Kazam, I., Gloff, J. L., Walder, A. H. D.: Post-Operative Radiation Therapy in the Management of Brain Astrocytoma - A retrospective study of 142 patients. Int. J. Radiat. Oncol. Biol. Phys. 7: 191-195, 1981.

26. Salazar, O., Rubin, P., Feldstein, M., Pizzutiello, R.: High Dose Radiation Therapy in the Treatment of Malignant Gliomas: Final Report Int. J. Radiat. Oncol. Biol. Phys. 5: 1733-1740, 1979.

27. Salazar, O. M., Rubin, P., McDonald, J. V., Feldstein, M. L.: Patterns of Failure in Intracranial Astrocytomas after Irradiation: Analysis of Dose and Field Factors. American J. Roent. Genol. Rad. Ther. Nucl. Med. 126: 279-292, 1976.

28. Salazar, O. M., Vanhoulte, P. J., Bennett, J. M., Rubin, P., Wheeler, K. T.: High dose radiation therapy with low-dose (pulsed) BCNU in malignant gliomas: An ECOG Report. Int. J. Radiat. Oncol. Biol. Phys. 8: 915-919, 1982.

29. Ten Haken, R. K., Awschalom, M., Hendrickson, F., and Rosenberg, I.: Comparison of the Physical Characteristics of a p(66)Be(49) Neutron Therapy Beam to Those of Correctional Radiotherapy Beams. Fermilab TM-1021R, 1980.

30. Urtasun, R. C., Band, P. R., Chapman, J. D., Feldstein, M. L.: Radiation Plus Metronidazole for Glioblastoma (note to the editor). NEJM: 296 757, 1977.

31. Urtasun, R. C., Chapman, J. D.: Radiation and High Dose Metronidazole in Supratentorial Glioblastomas. NEJM, 294: 1364-1367, 1976.

32. Walker, M. D., Hunt, A. E., MacCarty, W. E., Mahaley, C. S., Mealey, J., Norell, H. A., Owens, G., Ranschoff, J., Wilson, C. B., Gehan, E. A., Strike, T. A.: Evaluation of BCNU and/or Radiotherapy in the Treatment of Anaplastic Gliomas. A Cooperative Clinical Trial. J. Neurosurgery 49: 333-343, 1978.

33. Walker, M. D., Strike, T. A., Sheline, G. E., (for brain tumor study group). An Analysis of Dose-Effect Relationship in the Radiotherapy of Malignant Gliomas. Int. J. Radiat. Oncol. Biol. Phys. 5: 1725-1731, 1979.

Table 1

Histopathological Analysis

Source	Number of Patients	Residual Tumor	Radiation Necrosis
Autopsy	10	10	10
Post RT Craniotomy	5	5	5
Random Biopsy	1	?	1

Table 2

Comparison Between Neutrons + Misonidazole and Neutrons Only

(Restricted to Patients with Initial KPS 80-100)

Patients Characteristic	Neutron + Misonidazole	Neutron Only
Number of Evaluable Cases	21	23
Histology		
% Astrocytoma with atypical or anaplastic foci	29	17*
% Glioblastoma Multiforme	71	79
% Unknown/Missing	0	4
Age		
Mean	48.4	48.0
% <40 years	33	22
% 40-59 years	48	52
% ≥60 years	19	26
Extent of Surgery		
% None/Biopsy	0	39
% Partial Resection	100	44
% Complete	0	17
% Dead	100	83

*Only five of originally eight patients classified as astrocytoma were centrally reviewed.

Neutrons and Misonidazole for Malignant Astrocytomas

Table 3

Comparison of Neutrons ± Misonidazole,

Photon Only, Photon + Boost

(Restricted to Patients with Initial KPS 80-100 and with Glioblastoma Multiforme)

Patient Characteristics	Neutron ± Misonidazole	Photon Only	Photon + Photon Boost
Number of Evaluable Patients	33	44	33
Glioblastoma % Centrally Reviewed	58	100	100
Age			
Mean	50.5	47.2	48.6
% 40 years	18	27	30
% 40-59 years	55	59	46
% 60+ years	27	14	24
Extent of Surgery			
% None/Biopsy	21	17	16*
% Partial Biopsy	67	57	68
% Complete	12	26	16
% Dead	91	96	97

*Extent of prior surgery unknown in 1 patient.

List of Figures

Figure 1. Typical neutron isodose distribution for a patient treated for malignant astrocytoma.

Figure 2. Survival curve of 25 patients treated with neutrons and misonidazole for malignant astrocytomas.

Figure 3a. Pre-therapy CT scan. A frontoparietal malignant astrocytoma is demonstrated.

Figure 3b. CT scan of the same patient taken 7 months after neutrons and misonidazole.

Figure 4. Survival curves of 44 patients treated with neutrons only (-----) and with neutrons plus misonidazole (———), mean survival in either case was 12.5 months. Patients had a Karnofsky performance scale ≥80.

Figure 5. Survival curves of patients treated with neutrons only (———) mean survival 12 months, photons only (·····), mean survival 10 months, and photons + photon boost or neutron boost (-----) mean survival 12 months.

ISODOSES FOR GLIOBLASTOMA MULTIFORME OCCIPITAL LOBE

p(66) Be(49) NEUTRONS

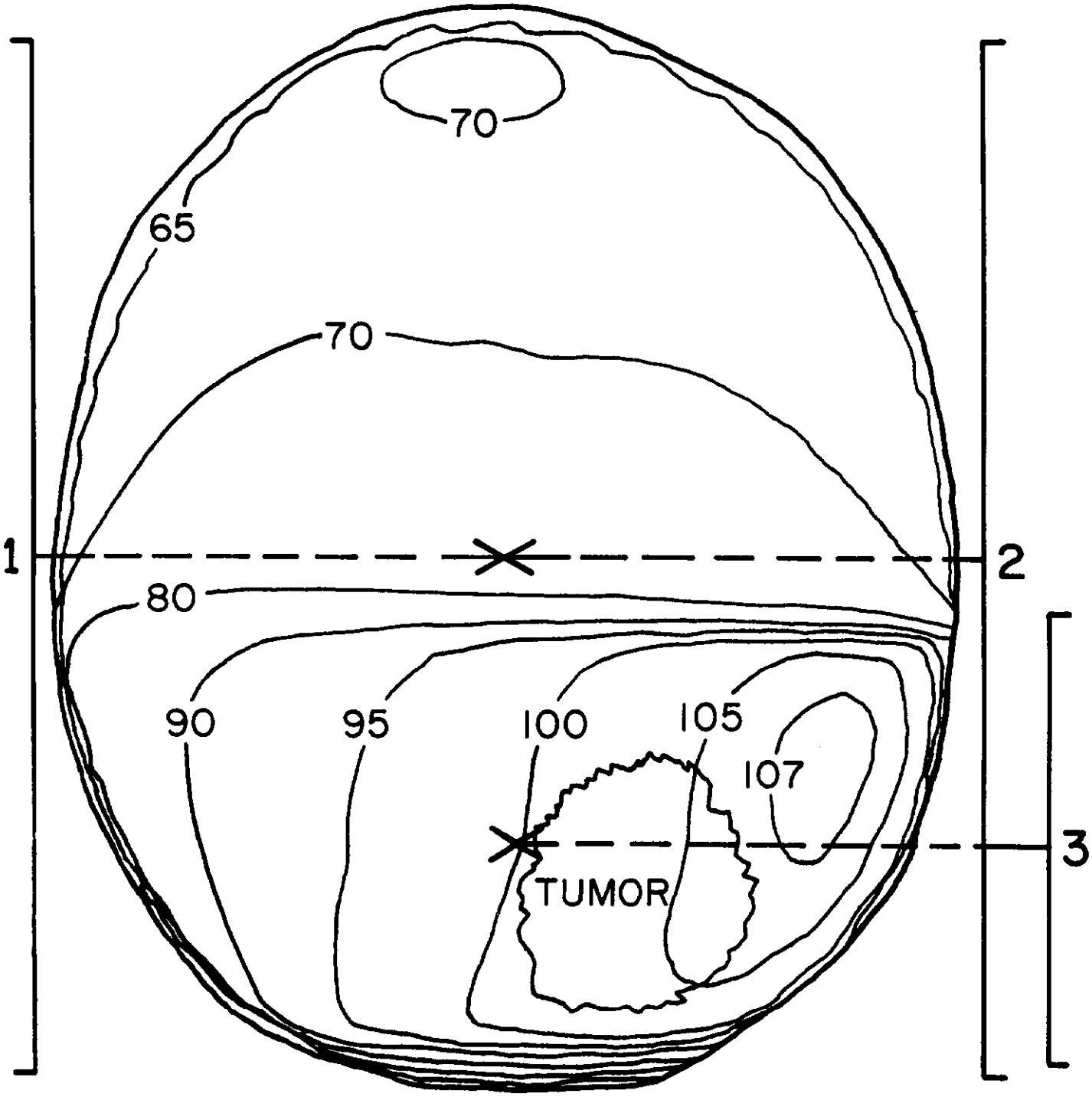

Figure 1

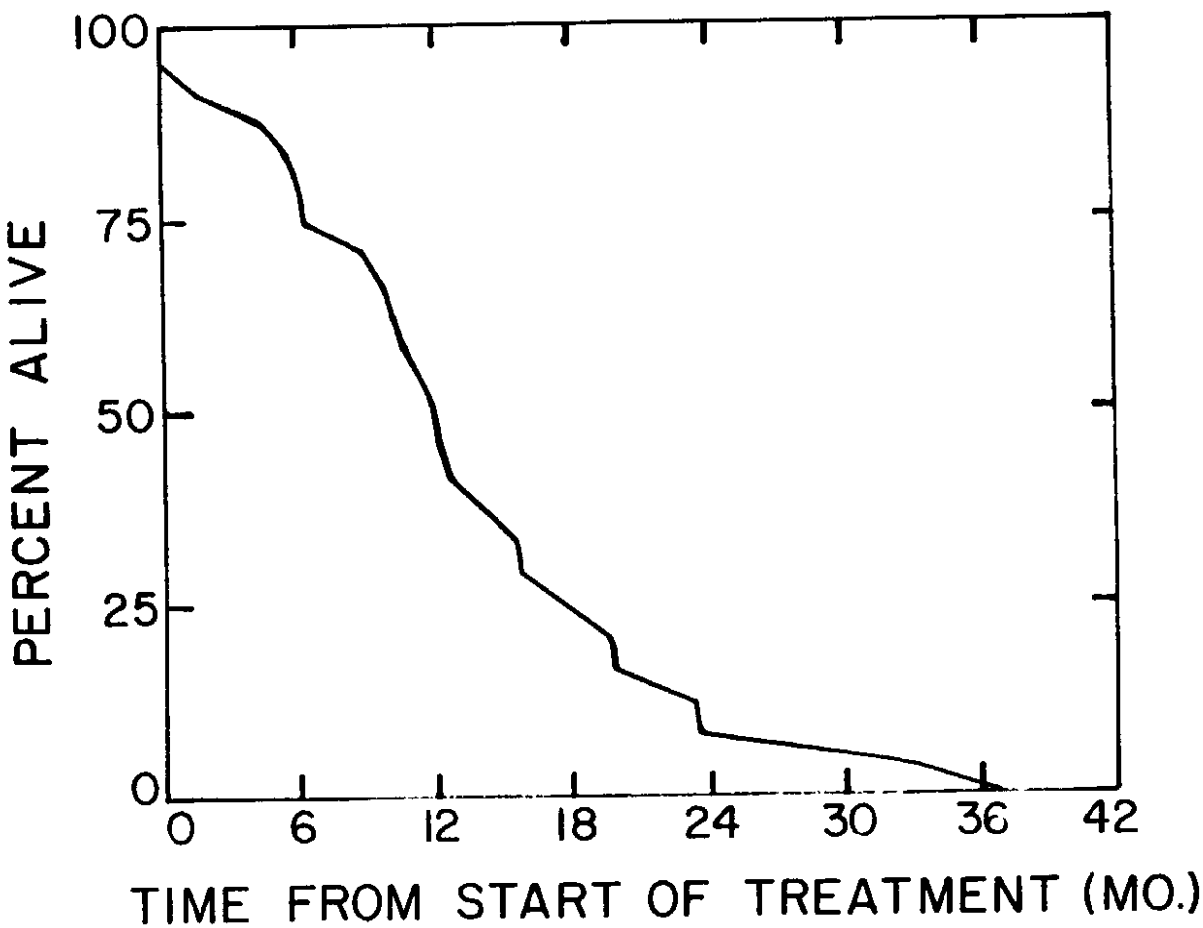
100
75
50
25
0
PERCENT ALIVE
0
6
12
18
24
30
36
42
TIME FROM START OF TREATMENT (MO.)

Figure 2

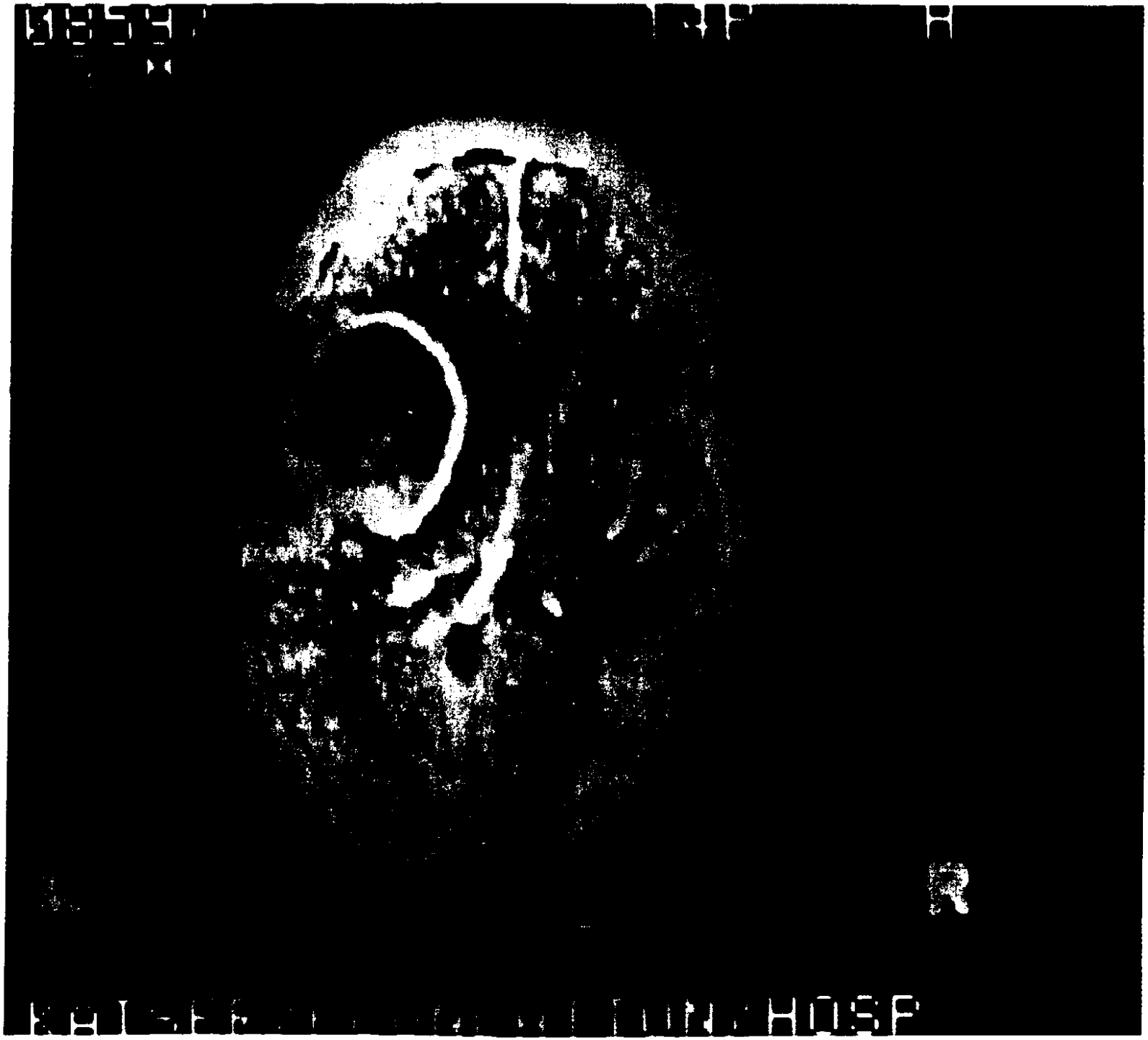

Figure 3a.

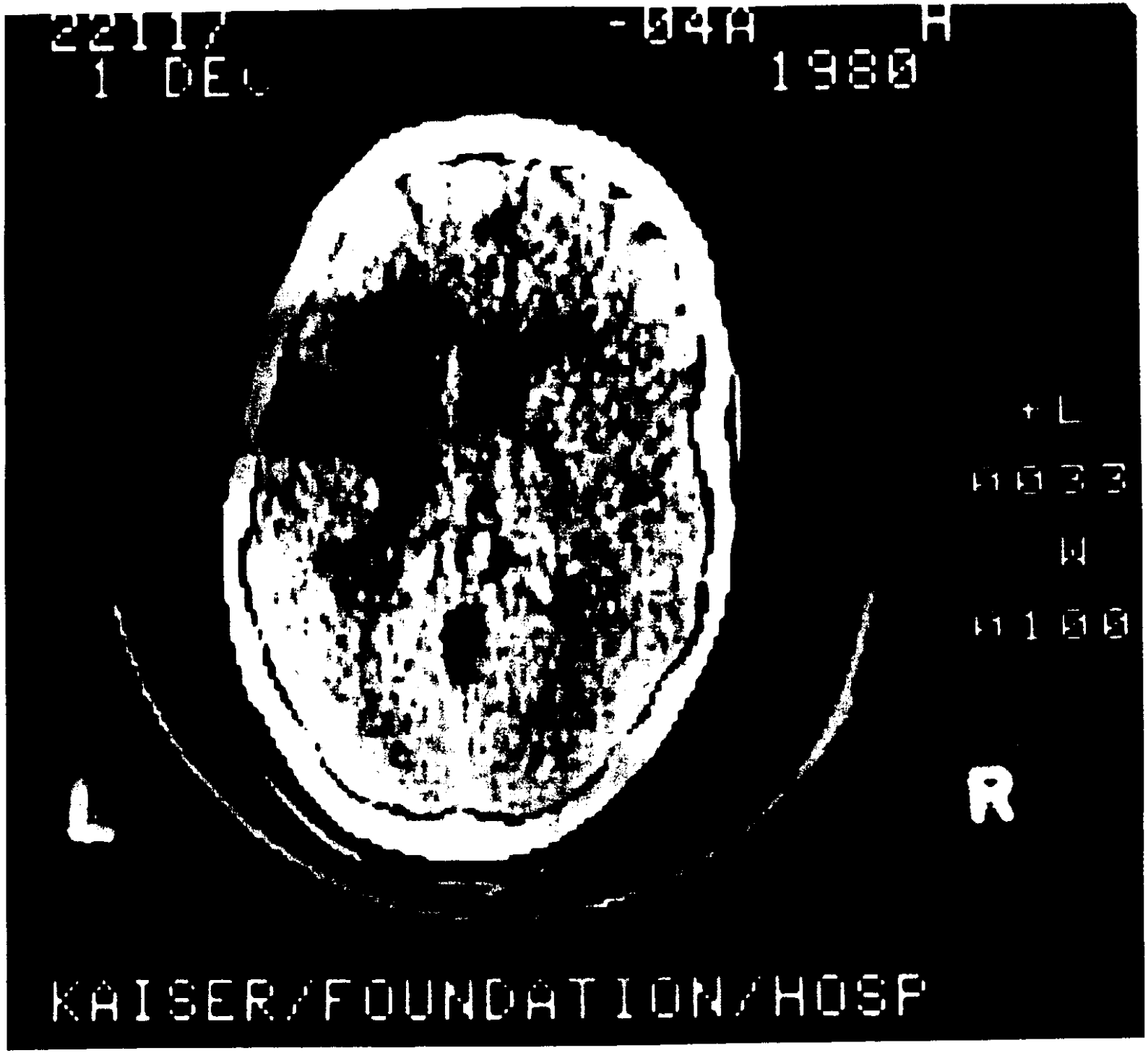

Figure 3b.

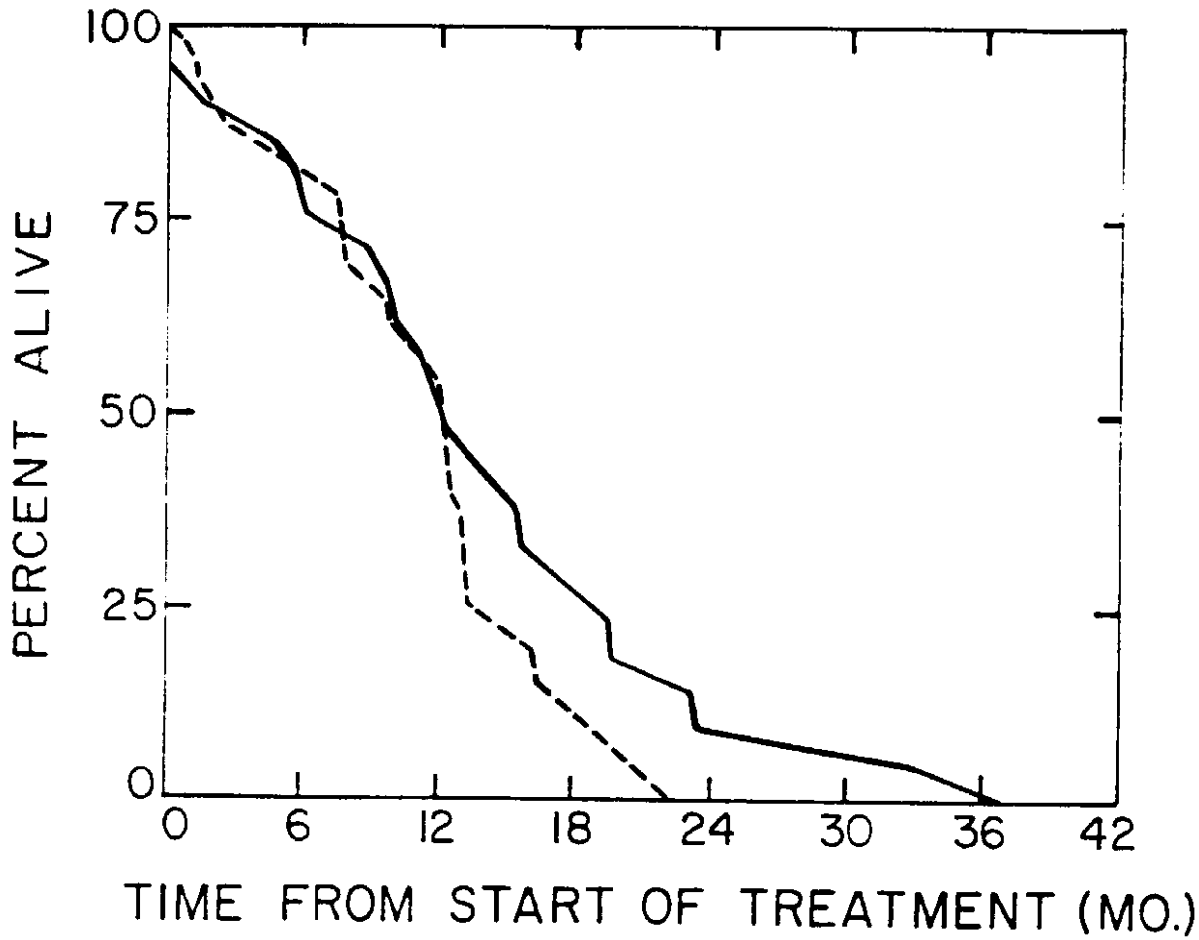
100
75
50
25
0
PERCENT ALIVE
0
6
12
18
24
30
36
42
TIME FROM START OF TREATMENT (MO.)

Figure 4

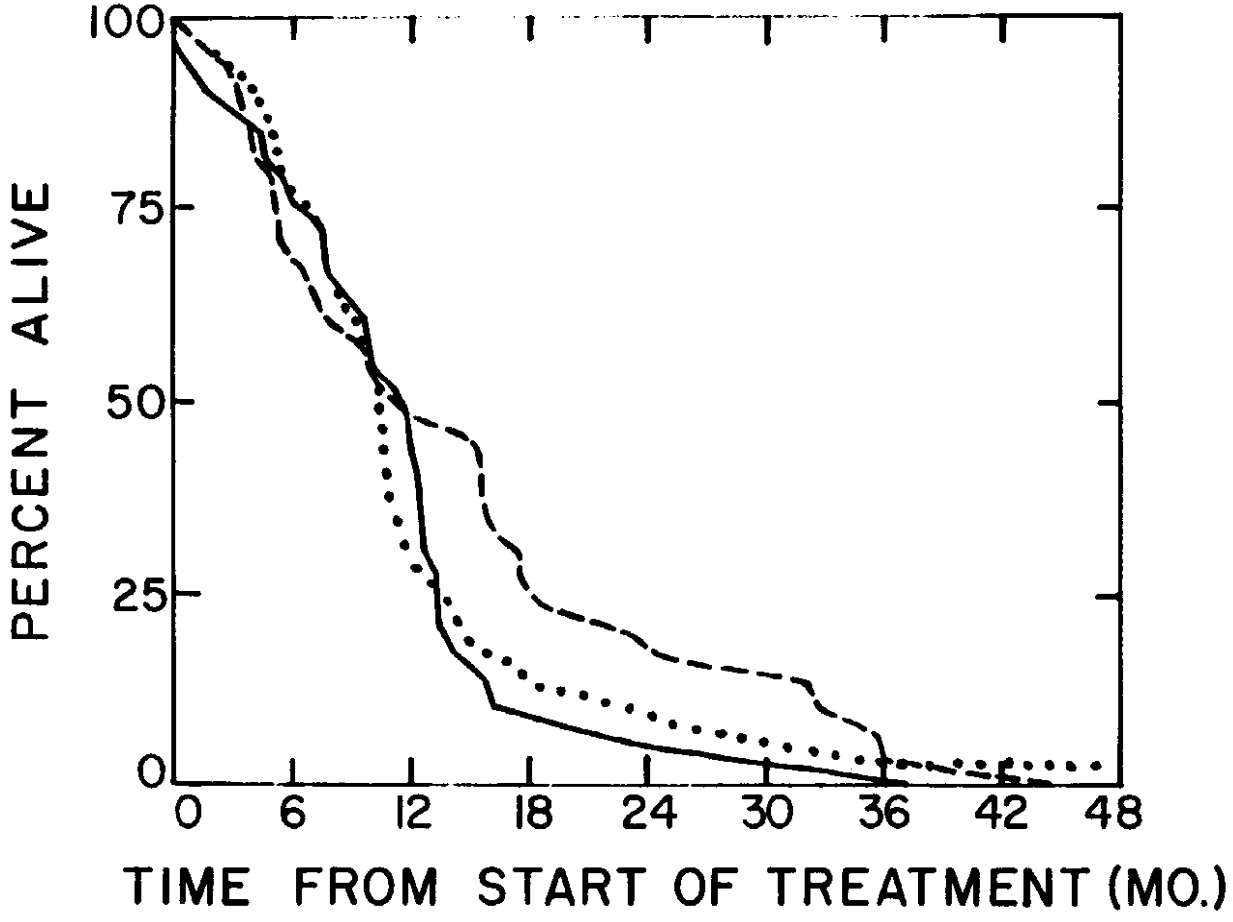
100
75
50
25
0
PERCENT ALIVE
0
6
12
18
24
30
36
42
48
TIME FROM START OF TREATMENT (MO.)

Figure 5